

# The Use of Visible Light Spectroscopy to Measure Tissue Oxygenation in Free Flap Reconstruction

Agustin Cornejo, M.D.,<sup>1,2</sup> Thomas Rodriguez, M.S.,<sup>1,2</sup> Megan Steigelman, M.D.,<sup>2</sup> Stacy Stephenson, M.D.,<sup>1,2</sup> David Sahar, M.D.,<sup>1,2</sup> Stephen M. Cohn, M.D.,<sup>2</sup> Joel E. Michalek, Ph.D.,<sup>3</sup> and Howard T. Wang, M.D.<sup>1,2</sup>

## ABSTRACT

The loss of a free flap is a feared complication for both the surgeon and the patient. Early recognition of vascular compromise has been shown to provide the best chance for flap salvage. The ideal monitoring technique for perioperative free flap ischemia would be noninvasive, continuous, and reliable. Visible light spectroscopy (VLS) was evaluated as a new method for predicting ischemia in microvascular cutaneous soft tissue free flaps. In an Institutional Review Board-approved prospective trial, 12 patients were monitored after free flap reconstructions. The tissue hemoglobin oxygen saturation (StO<sub>2</sub>) and total hemoglobin concentration (THB) of 12 flaps were continuously monitored using VLS for 72 hours postoperatively. Out of these 12 flaps 11 were transplanted successfully and 1 flap loss occurred. The StO<sub>2</sub> was 48.99% and the THB was 46.74% for the 12 flaps. There was no significant difference in these values among the flaps. For the single flap loss, the device accurately reflected the ischemic drop in StO<sub>2</sub> indicating drastic tissue ischemia at 6 hours postoperatively before the disappearance of implantable Doppler signals or clinical signs of flap compromise. VLS, a continuous, noninvasive, and localized method to monitor oxygenation, appeared to predict early ischemic complications after free flap reconstruction.

**KEYWORDS:** Visible light spectroscopy, free flap monitoring, free flap reconstruction, postoperative monitoring

Reconstruction of large soft tissue defects after trauma or surgical procedures typically requires autologous microvascular free tissue transfers. The success rate of these procedures ranges from 91 to 99% and depends on the continuous arterial inflow and venous outflow through patent microvascular anastomoses.<sup>1</sup> Free flap loss due to vascular compromise is a dreaded complica-

tion that can occur in 5 to 25% of cases, and 95% of losses occur within 72 hours of surgery.<sup>2,3</sup> It is essential to identify vascular compromise early in the postoperative period to maximize the chance of graft salvage. Traditionally, clinical examination of capillary refill, flap color, temperature, and bleeding patterns has been considered the goal standard to assess the viability of free flaps.<sup>4-7</sup>

<sup>1</sup>Division of Plastic and Reconstructive Surgery; Departments of <sup>2</sup>Surgery and <sup>3</sup>Epidemiology and Biostatistics, University of Texas Health Science Center at San Antonio, San Antonio, Texas.

Address for correspondence and reprint requests: Howard T. Wang, M.D., Chief, Division of Plastic and Reconstructive Surgery, 7703 Floyd Curl Drive, San Antonio, TX 78229-3900 (e-mail: wanght@uthscsa.edu).

J Reconstr Microsurg 2011;27:397-402. Copyright © 2011 by Thieme Medical Publishers, Inc., 333 Seventh Avenue, New York, NY 10001, USA. Tel: +1(212) 584-4662.

Received: November 10, 2010. Accepted after revision: April 26, 2011. Published online: June 29, 2011.  
DOI: <http://dx.doi.org/10.1055/s-0031-1281521>.  
ISSN 0743-684X.

This technique relies heavily on the experience and availability of hospital staff and is mostly useful for nonburied flaps, since by virtue of their location, buried flaps cannot be directly visualized. To overcome this limitation, some authors have advocated the creation of an external component also called monitoring flap (externalized skin or a vessel stump) which can be subsequently removed during a secondary procedure.<sup>8</sup> However, primary disadvantages of these modifications to buried flaps are additional technical complexity and need for additional procedures. Along with clinical examination, external handheld Doppler ultrasonography has also been commonly used to assess vascular patency; yet its utility in buried flaps is limited given that the localization of small vessels can be difficult since it requires transcutaneous access to recipient vessels.<sup>1</sup>

Due to the above-mentioned limitations, an increasing amount of microvascular surgeons are turning to other effective yet invasive techniques such as the implantable Cook-Swartz Doppler system.<sup>5,9-13</sup> Currently up to 48.7% of microsurgical centers in the United States use this technique along with clinical observation to monitor free flaps according to a recent survey of plastic surgery directors.<sup>5</sup> This technique consists of an implantable ultrasonic probe that is mounted directly around the vessel intended to be monitored which provides continual feedback on vascular pedicle status. Although this technique has proven to be efficacious in detecting ischemia in superficial and buried flaps, it is invasive and impractical for extremely small vessels. Furthermore, the implantable Doppler probe does not evaluate end-organ tissue perfusion which provides important information regarding the tissue viability.<sup>14</sup> Other less popular monitoring methodologies vary in complexity, efficacy, and invasiveness and include internal and external thermometry, pulse oximetry, quantitative fluorescein fluorescence, and transcutaneous oxygen monitoring.<sup>15-17</sup>

Visible light spectroscopy (VLS) was recently introduced as a continuous noninvasive method to detect hypoxemia and ischemia which appears to be simple to implement and interpret, and is inexpensive and well tolerated.<sup>18</sup> Compared with near-infrared spectroscopy (NIRS) and pulse oximetry, VLS oximetry uses shallow penetrating visible light (475 to 625 nm) to measure hemoglobin oxygen saturation (denoted as StO<sub>2</sub>) in small tissue volumes.<sup>14</sup> VLS has been demonstrated to monitor tissue perfusion accurately in several animal models and has detected ischemia during vascular surgery, tumor ablations, and gastrointestinal endoscopy.<sup>14,19,20</sup> However, there is limited data available using VLS technology to identify early flap ischemia following reconstructive surgery. This study was conducted to evaluate the utility of VLS for early identification of vascular compromise in microvascular free tissue transfers. We hypothesized that VLS monitoring

technique is comparable to clinical examination and implantable Doppler ultrasonography (main monitoring methods used at our institution) in detecting early vascular graft compromise while providing information about end-organ perfusion.

## METHODS

An Institutional Review Board-approved prospective trial was conducted looking at VLS monitoring of free flaps in 12 patients (32 to 87 years old) operated on between July 2008 and July 2009, in the Division of Plastic and Reconstructive Surgery, University of Texas Health Science Center at San Antonio. Of these 12 patients, 8 underwent fasciocutaneous flaps and 4 musculocutaneous flap reconstructions. Free tissue reconstruction followed ablative surgery for cancer (see Table 1). We obtained baseline StO<sub>2</sub> and total hemoglobin concentration (THB) measurements using VLS on the intact skin planned for use as the flap to ensure proper functioning of the device. We used the T-Stat Model 303VLS oximeter with a 2.4-cm diameter surface disk sensor (Spectros Corp., Portola Valley, CA) placed on the flap surface at the end of the operation and continuously monitored for 72 hours. In addition, an implantable Doppler probe was placed directly on the arterial vascular anastomoses in all flaps. All patients were monitored in the intensive care unit for at least 72 hours. Flaps were monitored by a physician and a nurse with hourly physical examination and continuous implantable Doppler. As per our institutional protocol, the nurses caring for the patients were instructed to promptly report the loss or change in the intensity of the implantable Doppler signal as well as any clinical signs of flap compromise. Even though changes in StO<sub>2</sub> and THB were followed, since VLS is still an experimental monitoring method in free flap reconstruction, the decision to reoperate was based on the surgeon's clinical judgment and the changes in the implantable Doppler signal. The Institutional Review Board of our institution approved the study protocol and all patients gave written informed consent before enrolling in the study.

**Table 1 Free Tissue Flap Donor Sites and Mean Tissue StO<sub>2</sub> and Mean THB in each Flap Group**

Flap Type	No.	Mean ± SEM StO <sub>2</sub> (%)	Mean ± SEM THB (%)
ALT	5	48.9 ± 11.7	33.6 ± 9.8
Fibula	4	54 ± 8.9	52.4 ± 19.9
RA	2	48.9 ± 18.3	47 ± 23.8
RF	1	29.1	88.9
Total	12	48.9 ± 6	46.7 ± 8.9

LAT, anterolateral thigh; RA, rectus abdominis; RF, radial forearm; SEM, standard error of the mean; StO<sub>2</sub>, hemoglobin oxygen saturation; THB, total hemoglobin concentration.

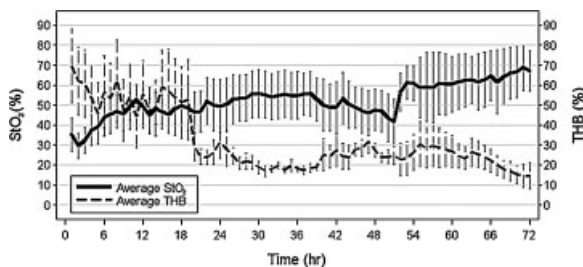
Statistical analysis: Changes in  $StO_2$  and THB were recorded continuously for 72 postoperatively in all flaps. The tissue oxygen values were expressed as mean  $\pm$  standard error of the mean (SEM). The significance of differences in tissue perfusion values were based on repeated measures linear models of the mean  $StO_2$  and THB in terms of time, flap type, and the time by flap type interaction (SAS Version 9.2 for Windows, SAS Institute, Cary, NC). A  $p$  value less than 0.05 was considered statistically significant.

## RESULTS

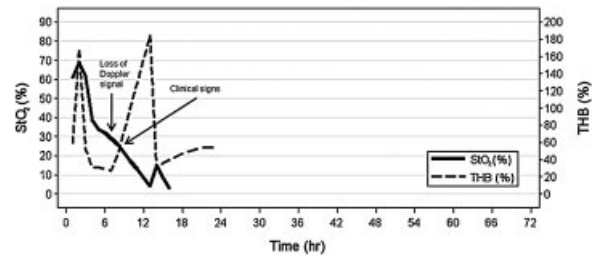
In this study 11 flaps were transplanted successfully and 1 flap failed, for an overall flap survival rate of 91%. The mean  $\pm$  SEM of  $StO_2$  and THB was  $48.99 \pm 6.08\%$  and  $46.76 \pm 8.98\%$ , respectively. There was no significant difference in  $StO_2$  ( $p = 0.71$ ) and THB ( $p = 0.57$ ) among the different types of flaps. There was a progressive increase in  $StO_2$  in the first 24 hours followed by a relative stabilization (Fig. 1). Also there was an initial decrease of THB during the first 6 hours postoperatively followed by stabilization of values and a second drop at  $\sim 24$  hours likely associated to a decrease in inflammatory response and venous congestion 24 hours after surgery.

### Flap Failure

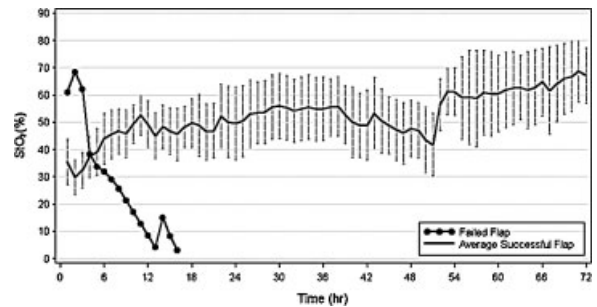
A free rectus abdominis muscle flap to the upper lip failed due to venous congestion which ultimately led to arterial thrombosis. The device accurately reflected the ischemic drop in  $StO_2$  at 6 hours postoperatively before the disappearance of implantable Doppler signals or clinical signs of flap compromise became apparent. The THB in this flap increased as the  $StO_2$  was falling suggesting a venous problem as the initial cause for failure (Fig. 2). The single patient with a flap failure experienced a drop in  $StO_2$  from 60% at time 0 to 0% at



**Figure 1** Mean tissue hemoglobin oxygen saturation ( $StO_2$ ) and total hemoglobin concentration (THB) during 72 hours postoperatively. There was a progressive increase in  $StO_2$  in the first 24 hours followed by a relative stabilization. Also there was an initial decrease of THB during the first 6 hours postoperatively followed by stabilization of values and a second drop at  $\sim 24$  hours likely associated to a decrease in inflammatory response and venous congestion 24 hours after surgery.



**Figure 2** Progressive ischemic drop in tissue hemoglobin oxygen saturation ( $StO_2$ ) and increase in total hemoglobin concentration (THB) in the single patient with a failed flap, suggesting a venous congestion as the leading cause for flap failure.



**Figure 3** Average tissue hemoglobin oxygen saturation ( $StO_2$ ) of successful flaps compared with the  $StO_2$  of the single patient with a failed flap.

17 hours (Fig. 3); the average slope of the  $StO_2$  curve ( $-4.9 \pm 8.2$ ) for this patient was significantly different from the average slope ( $0.4 \pm 8.4$ ) among the 11 patients without flap failure ( $p = 0.03$ ). The THB slope ( $-4.4 \pm 53.7$ ) for this patient did not differ significantly from the slope among the 11 patients without flap failure ( $-0.9 \pm 18.8$ );  $p = 0.23$ .

In another case, the  $StO_2$  levels dropped to considerably low levels ( $< 10\%$ ); however, there was not any clinical evidence of flap compromise and the Doppler signals were present. This case was then followed clinically and eventually did not need any intervention. Thus, the system gave one false-positive alarm.

## DISCUSSION

Free tissue transfer has become a routine intervention in the field of reconstructive surgery. When vascular complications threaten the viability of free flaps, salvage of these depends largely on the prompt recognition and early intervention. Therefore monitoring circulatory changes postoperatively is essential. Several techniques have been used as an adjunct to clinical assessment in an attempt to minimize failure rates; however, besides clinical assessment there is not a clinically accepted goal standard. This supports the search for sensitive and reliable alternatives.

Currently, NIRS is the basis for all other tissue oximeters approved for the clinical use in the United States.<sup>14</sup> Studies have shown that NIRS is capable of accurately identifying early signs of vascular compromise before clinical signs of flap failure occur with both a positive and negative predictive values of 100%.<sup>21–23</sup> However, one of the disadvantages of NIRS is that it is unsuitable to be applied to deeply sited tissue transfers and small tissues since its light sources and detectors must be placed 2 to 5 cm apart.<sup>1,18</sup> By contrast, VLS probes are very small (6 mm in diameter) and use light that is strongly absorbed by tissue. This is a major advantage of VLS over NIRS since it enables highly stable volume oximetry measurements in smaller tissues (< 125  $\mu$ L versus > 30 mL for NIRS) such as intraoral flaps.<sup>18</sup> A further advantage of this monitoring technique is its ability to look at end-organ perfusion which may be very helpful in monitoring the skin paddle of free fibula flaps as an example. Since VLS has shown to be reliable technique to monitor tissue ischemia, its potential advantages led us to investigate the effectiveness of this monitoring technique for tissue perfusion in the most critical 72 hours postoperatively after microvascular tissue transfers.<sup>14,18,19</sup>

In our study, VLS was used to monitor fasciocutaneous and musculocutaneous flaps. The average tissue saturation for all flaps was  $48.99\% \pm 6.08$  (mean  $\pm$  SEM) which falls within range compared with the normal saturation values reported for similar flaps.<sup>21,22,24,25</sup> Although there was not any significant difference in the mean StO<sub>2</sub> and THB among the flap types, there was significant variation in individual values and therefore we were not able to identify a critical range of StO<sub>2</sub> or THB directly associated with flap failure. The variation in StO<sub>2</sub> and THB values could potentially be reduced by comparing a larger sample of flaps. However, different types of flaps have different baseline StO<sub>2</sub> and THB ranges as well as different flow characteristics that can be affected by the underlying patient comorbidities. This could also explain, at least in part, the variability seen in our results.

Overall there was a progressive increase in StO<sub>2</sub> in the first 24 hours followed by a relative stabilization (Fig. 1). Najefi et al<sup>26</sup> reported an initial increase in StO<sub>2</sub> that is observed in successful flaps during the first 2 hours postoperatively with the use of NIRS. Such observation was made through a recent meta-analysis and was attributed to the autonomic denervation of the flaps during dissection and the postoperative inflammatory reaction which could explained our findings as well. Studies with NIRS have also shown an increase in total hemoglobin following successful free flap surgery, maintained up to 48 hours postoperatively, with subsequent recovery of levels toward preoperative values thereafter.<sup>26</sup> In our study there was an initial decrease during the first 6 hours postoperatively followed by stabilization of

values and a second drop at  $\sim$ 24 hours (Fig. 1). This decrease in THB could be explained by the decrease in the inflammatory response and venous congestion in the flaps that occurs 24 hours after surgery.

The VLS model that we used displays the oxygen saturation of the capillary hemoglobin and the relative total hemoglobin in the tissue at the measurement site. This combination of displayed values allows the differentiation between arterial and venous occlusions. In the former there is a drop in both saturation and total hemoglobin, and in the latter there is a drop in saturation but a stable or rising total hemoglobin value.<sup>24</sup> In the failed flap, the VLS device accurately reflected a progressive ischemic drop in StO<sub>2</sub> of nearly 50% of the baseline level at postoperative hour 6 (from 60 to 31%), suggesting the presence of tissue ischemia in the free rectus abdominis flap. In addition, the THB increased as the StO<sub>2</sub> was falling suggesting a venous problem as the leading cause for flap failure (Fig. 2). At the time of the initial decline in StO<sub>2</sub> there were no clinical signs of impending failure and a monophasic arterial signal from the implantable Doppler probe. Unfortunately, the patient became hemodynamically unstable in the postoperative period and we were unable to address any of the flap changes as the patient needed to be stabilized. Thus, by the time the flap compromise was suspected we could not take this patient to the operating room for revision. Subsequently, StO<sub>2</sub> continued to decline followed by the loss of the implantable Doppler signal at approximately hour 7 and then by considerable edema on the flap site at approximately hour 9 (Fig. 2). According to the data obtained from the VLS, the implantable Doppler and the clinical picture, the cause of flap failure was likely due to venous congestion which led to vascular thrombosis of the diseased arterial anastomosis. This could also explain why the arterial implantable Doppler signal, although decreased, persisted after the onset of VLS changes that suggested a venous outflow problem. In this respect we acknowledge that there are studies advocating a greater degree of sensitivity to venous obstruction when the implantable Doppler is placed on the venous anastomosis as opposed to the arterial anastomosis.<sup>27</sup> Thus, it is possible that using a venous probe may have prompted us to act sooner. However, in spite of our early suspicion of a venous outflow problem, due to the patient's health condition we could not act on the changes noted on the implantable arterial Doppler and our clinical examination.

In regards to the changes in StO<sub>2</sub> and THB levels and the appearance of clinical signs of flap compromise, the VLS identified inadequate flap perfusion  $\sim$ 3 hours before the physical appearance of flap distress. This is consistent with an observation reported in a study in which deep inferior epigastric perforator breast reconstructions were monitored using VLS.<sup>24</sup> In this study the StO<sub>2</sub> of the one flap that failed decreased markedly

(> 50% from baseline) at 7 hours postoperatively, nearly 2 hours before the presence of other clinical signs. Thus, VLS has the potential to detect inadequate tissue perfusion before it becomes clinically evident.

The StO<sub>2</sub> levels of the failed flap and the successful flaps are seen in Fig. 3 for comparison.

The VLS system gave one false-positive alarm where the StO<sub>2</sub> levels dropped to considerably low levels (StO<sub>2</sub> < 10%) and, on physician inspection, there were no clinical signs of flap compromise or changes in the implantable Doppler signal. A plausible explanation for this is the misplacement or dislodging of the VLS sensor probe which could have prevented sufficient contact with the skin of the patient. However, after the sensor probe was manipulated and appropriately attached to the skin, inaccurate measurements persisted and thus we cannot exclude a technical problem with the monitoring box system as the etiology for the obtained values.

At present, the cost for a VLS monitoring system consist of \$21,500 for the monitoring box and \$399 for the disposable sensor,<sup>24</sup> compared with \$16,000 for the NIRS monitoring box and \$150 for the sensor, and \$3100 for the implantable Doppler monitoring box and \$412 for each disposable probe.<sup>7</sup> In regards to the cost-effectiveness of VLS, further research will be necessary to compare each monitoring system for free flap reconstruction.

From our experience we can say that VLS is a noninvasive technique that is simple to implement, well tolerated, and continuous. It has the added advantage over the implantable Doppler monitoring in that it can measure end-organ perfusion and is noninvasive in nature. In addition, VLS has the potential to identify inadequate flap perfusion before the manifestation of physical signs of flap compromise. It is particularly useful if the trends in StO<sub>2</sub> and THB readings are interpreted on a case-by-case basis along with the clinical assessment of the flaps, since variations in flow characteristics among different types of flaps can occur. Further studies will be required to determine the cost-effectiveness and accuracy of VLS during reconstructive surgery. VLS technology has potential advantages to other monitoring techniques and may in fact be a useful complementary tool for monitoring ischemic changes in microvascular free tissue transfers.

#### ACKNOWLEDGMENT

The authors would like to acknowledge Spectros who contributed equipment to the study.

#### REFERENCES

1. Abdel-Galil K, Mitchell D. Postoperative monitoring of microsurgical free tissue transfers for head and neck reconstruction: a systematic review of current techniques—part I. Non-invasive techniques. *Br J Oral Maxillofac Surg* 2009;47(5):351–355
2. Bakri K, Moran SL. Monitoring for upper-extremity free flaps and replantations. *J Hand Surg Am* 2008;33(10):1905–1908
3. Chen KT, Mardini S, Chuang DC, et al. Timing of presentation of the first signs of vascular compromise dictates the salvage outcome of free flap transfers. *Plast Reconstr Surg* 2007;120(1):187–195
4. Disa JJ, Cordeiro PG, Hidalgo DA. Efficacy of conventional monitoring techniques in free tissue transfer: an 11-year experience in 750 consecutive cases. *Plast Reconstr Surg* 1999;104(1):97–101
5. Haddock NT, Gobble RM, Levine JP. More consistent postoperative care and monitoring can reduce costs following microvascular free flap reconstruction. *J Reconstr Microsurg* 2010;26(7):435–439
6. Jallali N, Ridha H, Butler PE. Postoperative monitoring of free flaps in UK plastic surgery units. *Microsurgery* 2005;25(6):469–472
7. Smit JM, Zeebregts CJ, Acosta R, Werker PM. Advancements in free flap monitoring in the last decade: a critical review. *Plast Reconstr Surg* 2010;125(1):177–185
8. Cho BC, Shin DP, Byun JS, Park JW, Baik BS. Monitoring flap for buried free tissue transfer: its importance and reliability. *Plast Reconstr Surg* 2002;110(5):1249–1258
9. Guillemaud JP, Seikaly H, Cote D, Allen H, Harris JR. The implantable Cook-Swartz Doppler probe for postoperative monitoring in head and neck free flap reconstruction. *Arch Otolaryngol Head Neck Surg* 2008;134(7):729–734
10. Rosenberg JJ, Fornage BD, Chevray PM. Monitoring buried free flaps: limitations of the implantable Doppler and use of color duplex sonography as a confirmatory test. *Plast Reconstr Surg* 2006;118(1):109–113, discussion 114–115
11. Rozen WM, Chubb D, Whitaker IS, Acosta R. The efficacy of postoperative monitoring: a single surgeon comparison of clinical monitoring and the implantable Doppler probe in 547 consecutive free flaps. *Microsurgery* 2010;30(2):105–110
12. Smit JM, Whitaker IS, Liss AG, Audolfsson T, Kildal M, Acosta R. Post operative monitoring of microvascular breast reconstructions using the implantable Cook-Swartz doppler system: a study of 145 probes & technical discussion. *J Plast Reconstr Aesthet Surg* 2009;62(10):1286–1292
13. Schmulder A, Gur E, Zaretski A. Eight-year experience of the Cook-Swartz Doppler in free-flap operations: microsurgical and reexploration results with regard to a wide spectrum of surgeries. *Microsurgery* 2011;31(1):1–6
14. Benaron DA, Parachikov IH, Cheong WF, et al. Design of a visible-light spectroscopy clinical tissue oximeter. *J Biomed Opt* 2005;10(4):44005
15. Abdel-Galil K, Mitchell D. Postoperative monitoring of microsurgical free-tissue transfers for head and neck reconstruction: a systematic review of current techniques—part II. Invasive techniques. *Br J Oral Maxillofac Surg* 2009;47(6):438–442
16. Keller A. Noninvasive tissue oximetry for flap monitoring: an initial study. *J Reconstr Microsurg* 2007;23(4):189–197
17. Luu Q, Farwell DG. Advances in free flap monitoring: have we gone too far? *Curr Opin Otolaryngol Head Neck Surg* 2009;17(4):267–269
18. Benaron DA, Parachikov IH, Friedland S, et al. Continuous, noninvasive, and localized microvascular tissue oximetry using visible light spectroscopy. *Anesthesiology* 2004;100(6):1469–1475
19. Karliczek A, Benaron DA, Baas PC, Zeebregts CJ, Wiggers T, van Dam GM. Intraoperative assessment of microperfusion

- with visible light spectroscopy for prediction of anastomotic leakage in colorectal anastomoses. *Colorectal Dis* 2010;12(10):1018-1025
20. Ho JK, Liakopoulos OJ, Crowley R, et al. In vivo detection of myocardial ischemia in pigs using visible light spectroscopy. *Anesth Analg* 2009;108(4):1185-1192
  21. Cai ZG, Zhang J, Zhang JG, et al. Evaluation of near infrared spectroscopy in monitoring postoperative regional tissue oxygen saturation for fibular flaps. *J Plast Reconstr Aesthet Surg* 2008;61(3):289-296
  22. Colwell AS, Wright L, Karanas Y. Near-infrared spectroscopy measures tissue oxygenation in free flaps for breast reconstruction. *Plast Reconstr Surg* 2008;121(5):344e-345e
  23. Repez A, Oroszy D, Arnez ZM. Continuous postoperative monitoring of cutaneous free flaps using near infrared spectroscopy. *J Plast Reconstr Aesthet Surg* 2008;61(1):71-77
  24. Spectros. Available at:<http://www.spectros.com>. Accessed August 9, 2010
  25. Schrey AR, Kinnunen IA, Grénman RA, Minn HR, Aitasalo KM. Monitoring microvascular free flaps with tissue oxygen measurement and PET. *Eur Arch Otorhinolaryngol* 2008;265(Suppl 1):S105-S113
  26. Najefi A, Leff DR, Nicolaou M, Nduka C, Yang GZ, Darzi AW. Monitoring of free flaps using near-infrared spectroscopy: a systematic review of the initial trials. *Plast Reconstr Surg* 2010;125(4):182e-184e
  27. Swartz WM, Izquierdo R, Miller MJ. Implantable venous Doppler microvascular monitoring: laboratory investigation and clinical results. *Plast Reconstr Surg* 1994;93(1):152-163